

# Micropulse Laser for Treatment of DME and CSC

The subthreshold modality avoids thermal damage to retinal tissues. Proper parameters are of paramount importance.

BY JOSÉ AUGUSTO CARDILLO, MD; AND MICHEL E. FARAH, MD, PhD

**T**hermal photocoagulation with continuous-wave (CW) laser has long been a standard-of-care treatment for both diabetic macular edema (DME)<sup>1</sup> and central serous chorioretinopathy (CSC).<sup>2</sup> Recently, however, new laser modalities have become available that offer the possibility of less destructive treatments for these diseases. Specifically, the micropulse modes now available on laser models from several manufacturers offer the potential to treat these conditions without burning the retina.

There is a growing literature on the use of subthreshold treatments with micropulse lasers. At our center, we have been using micropulse lasers for 14 years, and we have recently spent more than 2 years studying and refining the parameters of the micropulse laser therapy mode on the Iridex IQ 810 nm and 577 nm yellow laser for treatment of DME and CSC, two conditions characterized by fluid in or under the retina. Our clinical study results, as well as those from other centers, suggest that subthreshold micropulse laser may offer an alternative to thermal laser treatment for these conditions and may allow, particularly in CSC, treatment of eyes for which no therapy was previously available.

## DME

Our group and others have evaluated the use of diode micropulse laser for treatment of DME, comparing this new modality prospectively to conventional thermal laser, assessing efficacy and safety, and developing new

parameters and methods of laser application, such as the “sandwich grid.”

In a prospective, double-masked trial in 123 patients with DME, we compared the anatomic effects of modified ETDRS focal/grid thermal 532-nm laser photocoagulation vs subthreshold 810-nm diode micropulse laser photocoagulation using either a normal density or high-density treatment pattern.<sup>3</sup> At 1 year, the high-density subthreshold group had the most improvement in best corrected visual acuity (BCVA), followed by the modified ETDRS group. No improvement was seen with the normal-density subthreshold treatment. The high-density group also showed the greatest reduction in central macular thickness (CMT) as measured by optical coherence tomography (OCT).

This study demonstrates that when new technologies are introduced, it is vital to consider whether previous parameters and practices are appropriate or must be modified to make the new treatment work optimally. With subthreshold treatment in this study, the higher-density grid application produced the best outcomes. Although the reduction of laser intensity with subthreshold application reduces the negative effects of thermal coagulation, it also requires a compensatory increase in treatment density. This is one of the reasons we have spent considerable time and effort refining and optimizing the parameters for this new laser modality.

Others have reported findings similar to our own. Vujosevic et al<sup>4</sup> prospectively compared the results of

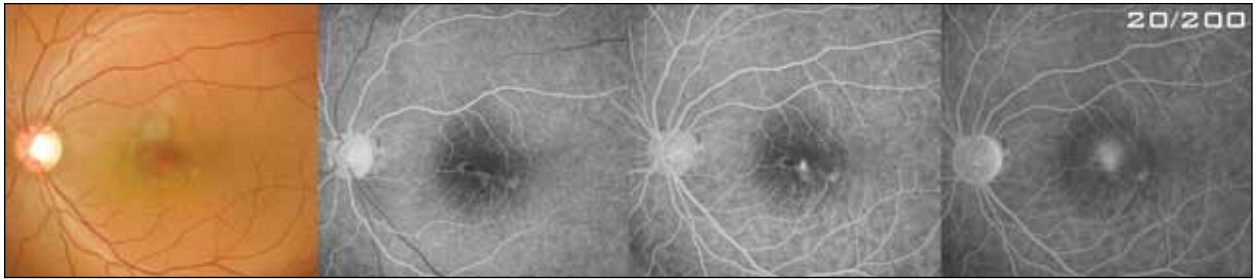


Figure 1. Patient with CSC with foveal leakage before micropulse laser treatment.

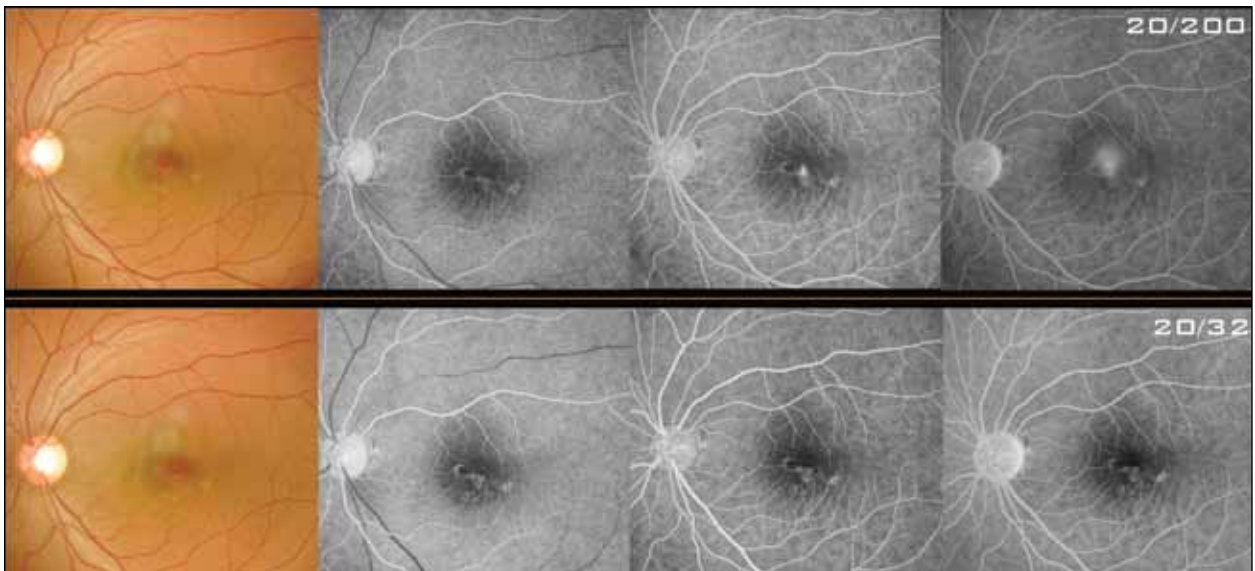


Figure 2. Same patient as Figure 1, 30 days post-treatment.

microperimetry and fundus autofluorescence (FAF) in 62 eyes of 50 patients undergoing either modified ETDRS laser or subthreshold micropulse laser treatment for DME. At 1 year, they reported that micropulse treatment was as effective as the modified ETDRS treatment. In the micropulse group, no changes indicating damage to the retinal pigment epithelium (RPE) were seen on FAF, and retinal sensitivity was increased as measured by microperimetry.

Luttrull and colleagues<sup>5</sup> this year published long-term safety results of 810-nm subthreshold micropulse treatment of DME, including patients treated as early as 2000. In 212 eyes with DME, CMT was reduced and no laser-induced retinal damage was seen.

An important consideration in the use of micropulse treatment is where the laser is delivered. We recently described the sandwich grid treatment technique,<sup>6</sup> in which a combination of CW and subthreshold micropulse laser is used to treat DME patients with foveal leakage. In this technique, CW 577-nm diode laser applies barely visible lesions in a grid pattern surround-

ing the fovea, up to 500  $\mu\text{m}$  from the center of the foveal avascular zone (FAZ). Then the laser is switched to micropulse mode, with a duty cycle of 10% or less, and subthreshold treatment is painted over all areas of leakage in the fovea and within 500  $\mu\text{m}$  of the center of the FAZ. In 28 eyes of 25 patients treated with this approach, at 6 months mean CMT was decreased by 201  $\mu\text{m}$  and mean improvement in visual acuity was 3 letters. Microperimetry showed that mean macular sensitivity improved at 3 and 6 months. CW laser lesions could not be clinically observed but were seen on fluorescein angiography (FA). No signs of the subthreshold treatment could be seen in the fovea by any means.

On the whole, these investigations suggest that micropulse mode can be used to minimize side effects of laser treatment while maintaining efficacy in the treatment of DME. Micropulse laser, especially if used with adjusted parameters and protocols such as the sandwich grid technique, may offer a more selective treatment alternative for DME.

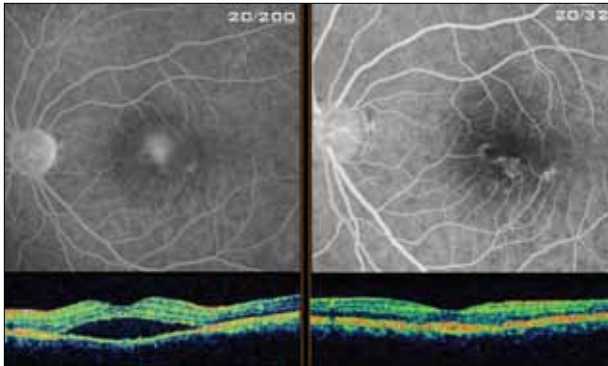


Figure 3. Same patient as Figure 1, pre- (left) and post-treatment fluorescein angiography and OCT images

### CSC

Micropulse laser can potentially be even more useful for treatment of CSC than for DME. We have always had the availability of conventional thermal laser for treatment of CSC outside the fovea, but what have we had to offer the CSC patient with focal or diffuse leakage affecting the macula? Foveal treatment with thermal laser will cause a permanent scotoma. Photodynamic therapy (PDT) is a reasonable alternative for treating persistent juxtafoveal or subfoveal leakage. However, PDT is associated with RPE atrophy, transient central scotoma, and choroidal neovascularization. In addition, although PDT has been associated with encouraging treatment outcomes in CSC and other choroidal vascular conditions, these are considered nonstandard indications for PDT.<sup>7</sup>

Rather than photocoagulating the fovea, selective micropulse laser may allow us to photostimulate the fovea, offering a new treatment tool for CSC.

We recently reported clinical outcomes with the use of a 577-nm micropulse laser photostimulation technique (577-nm subthreshold high-density macular grid) for treatment of chronic CSC with foveal and/or juxtafoveal leakage.<sup>8</sup> Ten eyes with persistent CSC and foveal leakage of longer than 4 months duration were treated using a yellow (577-nm) micropulse laser (Iridex IQ). All patients in the study were unsuitable for conventional laser treatment.

High-density focal and grid laser were delivered, targeting all angiographic leakage, including the fovea, as well as adjacent normal retina. The laser power was set individually. Main outcome measures were ETDRS BCVA and CMT using OCT at 6 months. Pre- and post-treatment FA, microperimetry, and retreatment rate were also assessed.

We detected no visible signs of clinical treatment on FA. Regarding functional results, an improvement of 3 lines or more of BCVA was seen in 6 (60%) eyes.

---

There is still a lack of optimized protocols for use of micropulse laser, whether for DME or CSC. As new lasers continue to come into the market, they must be used within strict and appropriate guidelines.

---

Microperimetry showed no laser-related damage to the treatment area. Nine eyes (90%) required only 1 treatment. Anatomic outcomes were also excellent: Complete fluid resolution was seen in all eyes (100%) at 15 to 30 days after treatment (Figures 1-3). Eyes with focal and diffuse leakage showed equal degrees of anatomic response.

### DISCUSSION AND CONCLUSIONS

The clinical response and low retreatment rate seen in our recently reported series of eyes with CSC, using subthreshold photostimulation to treat affected areas as well as extending into normal retina, supports this approach as a possibly more comprehensive and selective laser strategy for treatment of CSC patients with foveal leakage.

There is still a lack of optimized protocols for use of micropulse laser, whether for DME or CSC. As new lasers continue to come into the market, they must be used within strict and appropriate guidelines. Otherwise, we are likely to use too much energy and photocoagulate the fovea, or use too little energy and achieve no effect.

Although we have the most experience with the Iridex IQ 577 and IQ 810 models, it should be noted that lasers from other manufacturers also offer micropulse settings, and we have used lasers made by these other companies as well. Other micropulse lasers include the Optos Mitra (586 nm yellow) and FastPulse (810 nm infrared), and the Quantel Supra 532 nm (green) and 660 nm (red) models. The red and green wavelengths of the Quantel laser may be less applicable to the treatments discussed in this article than yellow and infrared wavelengths.

Regardless of whether infrared or yellow laser is used, the most important factor for good outcomes with micropulse-mode lasers in DME and CSC is the selection and use of proper laser parameters and treatment guidelines. These are key for achieving optimal outcomes.

In patients with DME, we must be selective in treating around the fovea with laser to avoid causing irreversible damage to these sensitive tissues. We cannot do this with

standard thermal laser, but micropulse laser now offers the opportunity to safely, effectively address foveal leakage in DME with a subclinical, invisible laser treatment. Similarly, the take-home message of our CSC study is that we do not need to burn the retina in order to achieve good clinical results in patients with CSC affecting the fovea. We can photostimulate the foveal area safely.

To use an analogy, all drugs have a therapeutic and a toxic dose—the same drug at different dosages can cure us or kill us. The same rationale can now be applied to laser.

We envision future DME treatment combining anti-VEGF therapy and laser, but an optimized laser delivered according to refined treatment protocols. This may be a complementary combination, with the drug providing a better outcome than laser treatment alone, or the laser diminishing the need for repeated intravitreal injections. ■

*José Augusto Cardillo, MD, is Research Coordinator, Department of Retina and Ocular Pharmacology, Federal University of São Paulo, Brazil, and Chief of the Retina Department at the Hospital de Olhos de Araraquara. Dr. Cardillo states that he is a speaker for Iridex. He may be reached at [augustocardillo@me.com](mailto:augustocardillo@me.com).*



*Michel Eid Farah, MD, PhD, is an Associate Professor of Ophthalmology in the vitreoretinal surgery unit, Department of Ophthalmology, Vision Institute, Federal University of São Paulo, Brazil. He states that he has no financial interest in the products discussed in this article. Dr Farah may be reached at [mefarah@uol.com.br](mailto:mefarah@uol.com.br).*



high-resolution imaging, and tissue temperature modeling of subvisible diode micropulse photocoagulation for retinovascular macular edema. *Retina*. 2012;32(2):375-386.

6. Peroni R, Cardillo JA, Dare AJ, Aguirre JG, Lavinsky D, Farah ME, Belfort R Jr. A combined low energy, short pulsed 577 nm mild macular grid photocoagulation with 577 nm-micropulsed central laser stimulation for diabetic macular edema with foveal leakage (the sandwich grid). Paper presented at: Association for Research in Vision and Ophthalmology; May 1, 2011; Fort Lauderdale, FL.

7. Chan WM, Lim TH, Pece A, Silva R, Yoshimura N. Verteporfin PDT for non-standard indications—a review of current literature. *Graefes Arch Clin Exp Ophthalmol*. 2010;248(5):613-626.

8. Cardillo JA, Daré A, Lavinsky D, Farah ME. 577 selective subthreshold laser photocoagulation for the treatment of central serous retinopathy with foveal leakage. Paper presented at: Retina Society annual meeting; September 21-25; Rome, Italy.

1. No authors listed. Photocoagulation for diabetic macular edema. Early Treatment Diabetic Retinopathy Study report number 1. Early Treatment Diabetic Retinopathy Study research group. *Arch Ophthalmol*. 1985;103(12):1796-1806.

2. Roeder J, Brinkmann R, Wirbelauer C, Laqua H, Birngruber R. Retinal sparing by selective retinal pigment epithelial photocoagulation. *Arch Ophthalmol*. 1999;117(8):1028-1034.

3. Lavinsky D, Cardillo JA, Melo LAS, Dare A, Farah ME, Belfort R. Randomized clinical trial evaluating mETDRS versus normal or high-density micropulse photocoagulation for diabetic macular edema. *Invest Ophthalmol Clin Sci*. 2011;52(7):4314-4323.

4. Vujosevic S, Bottega E, Casciano M, Pilotto E, Convento E, Midena E. Microperimetry and fundus autofluorescence in diabetic macular edema: subthreshold micropulse diode laser versus modified early treatment diabetic retinopathy study laser photocoagulation. *Retina*. 2010;30(6):908-916.

5. Luttrull JK, Sramek C, Palanker D, Spink CJ, Musch DC. Long-term safety,